

OFFICE OF THE MEDICAL EXAMINER  
COUNTY OF COOK

NAME Laquan McDonald

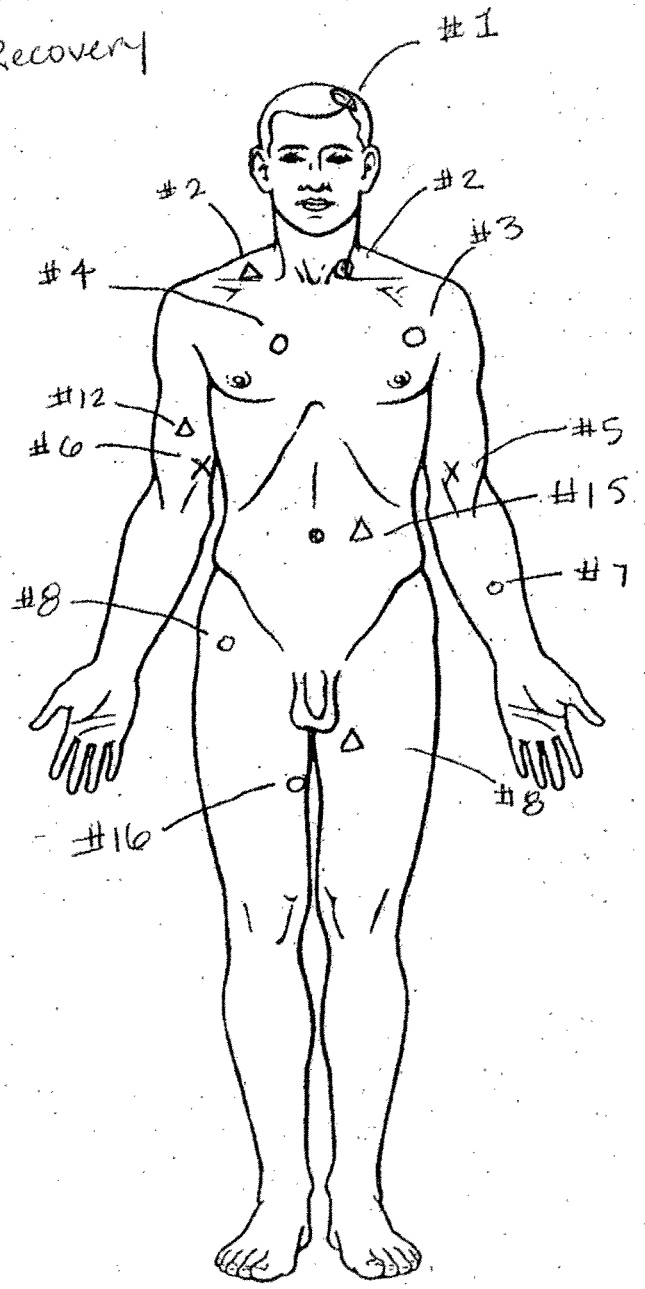
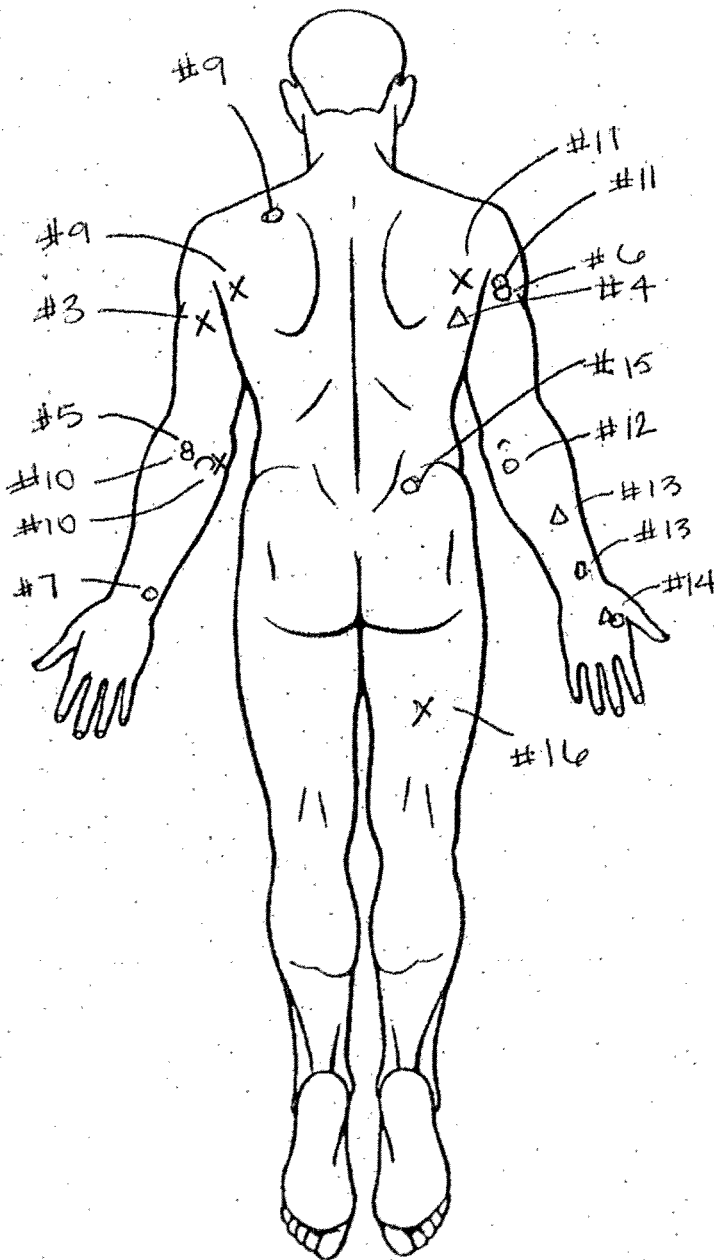
CASE NO. ME2014-01071

AGE 17 y SEX M RACE B

o = Entrance

X = Exit

Δ = Recovery



DM

**OFFICE OF THE MEDICAL EXAMINER  
COUNTY OF COOK, ILLINOIS**

**REPORT OF POSTMORTEM EXAMINATION**



**NAME** MCDONALD, LAQUAN

**CASE NO.** ME2014-01071

**AGE** 17y    **RACE** BLACK    **SEX** MALE

**DATE OF DEATH** OCTOBER 20, 2014

**DATE EXAMINED** OCTOBER 21, 2014 (8:25am)    **EXAMINED BY** Denika Means, DO

Investigator Daniel Kobel with the City of Chicago Independent Police Review Authority is present for the autopsy.

**EXTERNAL EXAMINATION**

The body is identified by toe tag. Photographs and radiographs are taken.

When first viewed, the body is clad in a green hospital gown. A tan rubber band encircles the right wrist. Accompanying the body is a black, hooded, zip-up sweatshirt (cut), a black with white lettering sweatshirt, blue jeans, black boxers (cut), two black shoes and two black socks. No jewelry is present. All of the clothing is relinquished to a representative of the Chicago Police Department.

The body is that of a well-developed, well-nourished, black male whose appearance is compatible with the stated age of 17 years. As received, the body weighs 180 pounds and is 72 inches long. There is good preservation in the absence of embalming. The body is warm, rigor mortis is easily broken, and lividity is not apparent.

The black scalp hair is in dreadlocks up to 5 inches long. An average amount of body hair is in a normal male distribution. The irides are brown, the corneae are clear, and there are no petechiae of the bulbar or palpebral surfaces of the conjunctivae. The ears, nose and lips are unremarkable. The teeth are natural and in good condition with absence of the upper left central incisor. The neck and chest are symmetrical, and the abdomen is flat. The external genitalia, anus and perineum are unremarkable. The extremities are well developed and symmetrical. The back is straight.

### IDENTIFYING MARKS AND SCARS

A black ink tattoo on the right upper arm reads "Quan". A black ink tattoo on the dorsum of the right hand reads "Good Son". On the dorsum of the left hand is a black ink tattoo that reads "YOLO" and has a pair of dice.

### EVIDENCE OF THERAPY

An endotracheal tube is in the mouth. Intravascular lines are in the left groin and left antecubital fossa. An intraosseous line is in the left shin. A loosely sutured incision runs from the right midaxillary line to the left lateral back just inferior to the nipple line.

### EVIDENCE OF INJURY

#### **I. Multiple Gunshot Wounds:**

There are 16 gunshot wounds, numbered 1 through 16 arbitrarily without regard to sequence or severity.

##### **1. GUNSHOT WOUND OF THE LEFT SCALP:**

There is a gunshot graze wound of the left parietal scalp centered 1-1/2 inches from the top of the head and 1/2 inch anterior to the superior attachment of the pinna of the left ear. The gaping wound is 1-3/4 inches long and up to 1/4 inch deep, extending to the fascia overlying the skull. The wound has no marginal abrasion, soot, or stippling.

Associated with this wound, there is mild left temporoparietal subscapular hemorrhage. Thin subarachnoid hemorrhage overlies the left temporal and parietal lobes of the brain.

Directionality cannot be determined.

##### **2. GUNSHOT WOUND OF THE NECK:**

There is a gunshot wound of entrance of the left base of the neck located 11 inches from the top of the head and 2 inches left of anterior midline. The circular wound is 3/16 inch in diameter and has a circumferential dry red-brown marginal abrasion that measures up to 1/4 inch at 12 o'clock, 1/8 inch at



3 o'clock, 1/4 inch at 6 o'clock, and 3/16 inch at 9 o'clock. There is no soot or stippling.

After perforating the skin and subcutaneous tissue of the left side of the neck, the bullet subsequently perforates the strap muscles of the left side of the neck, the trachea and the scalene muscles of the right side of the neck.

A moderately deformed, copper-jacketed, medium caliber bullet is recovered from the right supraspinatus muscle, at approximately 12 inches from the top of the head and approximately 5 inches right of anterior midline. The bullet is photographed, sealed within an appropriately labeled envelope and submitted to a representative of the Chicago Police Department.

Associated with this wound is hemorrhage and pulpification of the wound track.

The direction is left to right, slightly front to back and slightly downward.

### **3. GUNSHOT WOUND OF THE LEFT CHEST:**

There is a gunshot wound of entrance of the left upper chest located 12-1/4 inches from the top of the head and 5 inches left of anterior midline. The ovoid wound measures 1/2 x 1/2 inch and has a circumferential, dry, red-brown marginal abrasion that measures 1/16 inch at 12 o'clock, 1/8 inch at 3 o'clock, 1/16 inch at 6 o'clock and 1/8 inch at 9 o'clock. There is no soot or stippling.

After perforating the skin and subcutaneous tissue of the left upper chest, the bullet subsequently perforates the left pectoralis muscles, the muscles of the left lateral back, the muscles of the posterior left upper arm and the subcutaneous tissue and skin of the left upper arm.

A gunshot wound of exit of the posterior left upper arm is located 4-3/4 inches from the top of the left shoulder and 3/4 inch lateral to the posterior midline of the left arm. The ovoid wound measures 5/16 x 3/16 inch and has a circumferential brown marginal abrasion that is less than 1/16 inch wide. There is no soot or stippling.

Associated with this wound is hemorrhage and pulpification of the wound track.

The direction is front to back, right to left and downward.

#### **4. GUNSHOT WOUND OF THE RIGHT CHEST:**

There is a gunshot wound of the right side of the chest located 15-1/8 inches from the top of the head and 1-1/4 inches right of anterior midline. The circular wound is 3/16 inch in diameter and has a circumferential, dry, brown marginal abrasion that measures 1/16 inch at 12 o'clock, 3/16 inch at 3 o'clock, 1/16 inch at 6 o'clock and 1/16 inch at 9 o'clock. There is no soot or stippling.

After perforating the skin and subcutaneous tissue of the right side of the chest, the bullet subsequently perforates the right pectoralis muscles, the anterior portion of the right fourth rib and right fourth intercostal muscle, the right upper pulmonic lobe (x2), the right middle pulmonic lobe and the lateral portion of the right sixth intercostal muscle.

A markedly deformed, copper-jacketed bullet is recovered from the right latissimus dorsi muscle at a point approximately 18 inches from the top of the head and approximately 2 inches posterior to the right midaxillary line.

Associated with this wound is an anterior fracture of the right fourth rib and an approximately 40mL right hemothorax. There is hemorrhage and pulpification of the wound track.

The direction is front to back, left to right and slightly downward.

#### **5. GUNSHOT WOUND OF THE LEFT ELBOW:**

There is a gunshot wound of entrance of the lateral left elbow located 12-3/4 inches from the top of the left shoulder and 1-1/4 inches lateral to the posterior midline of the left arm. The circular wound measures 5/16 of an inch and has a 1/16 inch dark circumferential marginal abrasion. There is no soot or stippling.

After perforating the skin and subcutaneous tissue of the lateral left elbow, the bullet subsequently perforates the left humerus and the musculature, subcutaneous tissue and skin of the left upper arm.

A gunshot wound of exit of the medial left upper arm is located 11-1/4 inches from the top of the left shoulder and along the medial midline of the left arm. The irregularly-shaped wound is 1/2 x 1/2 inch. A 1/8 inch brown marginal abrasion extends from 1 o'clock to 3 o'clock and a 1/16 inch brown marginal abrasion extends from 11 o'clock to 12 o'clock. There is no soot or stippling.

Associated with this wound is a 3/16 inch dark brown, abraded skin bridge that separates the entrance gunshot wound #5 (superior) from the entrance gunshot wound #10 (inferior). There is a fracture of the distal left humerus as well as hemorrhage and pulpifaction of the wound track.

The direction is left to right, back to front and slightly upward.

#### **6. GUNSHOT WOUND OF THE RIGHT UPPER ARM:**

There is a gunshot wound of entrance of the posterior right upper arm located 6-1/2 inches from the top of the right shoulder and along the posterior midline of the right arm. The circular wound is 3/16 inch in diameter and has a 1/16 inch dry, dark marginal abrasion extending from 1 o'clock to 11 o'clock. There is no soot or stippling.

After perforating the skin and subcutaneous tissue of the posterior right upper arm, the bullet subsequently perforates the musculature of the right upper arm, the right humerus and the musculature, subcutaneous tissue and skin of the medial right upper arm.

There is a shored gunshot wound of exit of the medial right upper arm located 10-3/4 inches from the top of the right shoulder and along the medial midline of the right arm. The irregularly-shaped wound measures 7/16 x 5/16 inch and has a dry, dark circumferential marginal abrasion that measures 1/16 inch at 12 o'clock and 3 o'clock, 1/4 inch at 6 o'clock and 1/16 inch at 9 o'clock. There is no soot or stippling.



Associated with this wound is an abraded 3/4 inch moist pink skin bridge that separates the entrance gunshot wound #6 (inferior) from the entrance gunshot wound #11 (superior). There is also a fracture of the right humerus and hemorrhage and pulpification of the wound track.

The direction is back to front, downward and slightly left to right.

#### **7. GUNSHOT WOUND OF THE LEFT FOREARM:**

There is a gunshot wound of entrance of the dorsal left forearm located 19 inches from the top of the left shoulder and 1/2 inch medial to the posterior midline of the left arm. The ovoid wound measures 1/4 x 3/16 inch and has a circumferential dry dark marginal abrasion that measures 1/8 inch at 12 o'clock and 1/16 inch at 3, 6, and 9 o'clock. There is no soot or stippling.

After perforating the skin and subcutaneous tissue of the left forearm, the bullet subsequently perforates the left radius and ulna and the musculature, subcutaneous tissue and skin of the medial left forearm.

A gunshot wound of exit of the medial left forearm is located 20-1/2 inches from the top of the left shoulder and 1/2 inch anterior to the medial midline of the left arm. The ovoid wound measures 5/16 x 1/4 inch and has an ellipse-shaped marginal abrasion that measures 1/4 inch at 12 o'clock, 3/16 inch at 3 o'clock and 6 o'clock and 1/8 inch at 9 o'clock. There is no soot or stippling.

Associated with this wound are fractures of the left radius and ulna. There is hemorrhage and pulpification of the wound tracks.

The direction is back to front, slightly right to left and slightly downward.

#### **8. GUNSHOT WOUND OF THE LATERAL RIGHT UPPER LEG:**

There is a gunshot wound of entrance of the lateral right upper leg located 35-9/16 inches from the top of the head and 1-3/4 inches right of the anterior midline of the right leg.

The circular wound measures 1/4 inch in diameter and has a less than 1/16 inch marginal abrasion extending from 5 o'clock to 6 o'clock. The margin is extensively lacerated and has a circumferential 1/16 inch purple contusion. There is no soot or stippling.

After perforating the skin and subcutaneous tissue of the lateral right upper leg, the bullet subsequently perforates the musculature of the right upper leg, the pelvic floor musculature and the musculature of the medial left upper leg.

A moderately deformed, copper-jacketed, medium caliber bullet is recovered from the medial left upper leg at a point approximately 39 inches from the top of the head and approximately 2 inches right of anterior midline of the left leg. The bullet is photographed, sealed within an appropriately labeled envelope and submitted to a representative of the Chicago Police Department.

Associated with this wound is hemorrhage and pulpification of the wound track.

The direction is right to left, downward and slightly front to back.

#### **9. GUNSHOT WOUND OF THE LEFT UPPER BACK:**

There is a gunshot wound of entrance of the left upper back located 11 inches from the top of the head and 4-1/2 inches left of posterior midline. The irregularly-shaped wound measures 9/16 x 5/16 inch and has an irregular, circumferential brown marginal abrasion that measures 1/4 inch at 12 o'clock, 1/16 inch at 3 o'clock, 1/8 inch at 6 o'clock and 3/16 inch at 9 o'clock. There is no soot or stippling.

After perforating the skin and subcutaneous tissue of the left upper back, the bullet subsequently perforates the musculature of the left upper back and the subcutaneous tissue and skin of the left lateral back.

There is a gunshot wound of exit of the left lateral back located 17-1/4 inches from the top of the head and 3-1/2 inches posterior to the left midaxillary line. The irregularly-shaped wound measures 3/8 x 3/16 inch. There is no marginal abrasion, soot or stippling.



Associated with this wound is hemorrhage and pulpifaction of the wound track.

The direction is right to left and downward with no significant forward or backwards deviation.

**10. GUNSHOT WOUND OF THE LEFT ELBOW:**

There is a gunshot wound of entrance of the lateral left elbow which is located 13-1/16 inch from the top of the left shoulder and 1 inch lateral to the posterior midline of the left arm. The circular wound measures 3/16 inch in diameter and has a circumferential marginal abrasion that measures 1/8 inch at 12 o'clock and 3 o'clock and 1/16 inch at 6 o'clock and 9 o'clock. There is no soot or stippling.

After perforating the skin and subcutaneous tissue of the lateral left elbow, the bullet subsequently perforates the musculature of the lateral left elbow, the left humerus and the musculature, subcutaneous tissue and skin of the medial left elbow.

There is a gunshot wound of exit of the medial left elbow located 14-1/2 inches from the top of the left shoulder and 3/4 inch medial to the posterior midline of the left arm. The irregularly-shaped wound measures 3/16 x 1/8 inch. It has a circumferential marginal abrasion that measures 1/4 inch at 12 o'clock, 3/16 inch at 3 o'clock, less than 1/16 inch at 6 o'clock and 3/16 inch at 9 o'clock. There is no soot or stippling.

Associated with this wound (as mentioned above) is a 3/16 inch dark brown, abraded skin bridge that separates the entrance gunshot wound #5 (superior) from the entrance gunshot wound #10 (inferior). There are fractures of the left humerus and ulna as well as hemorrhage and pulpifaction of the wound track.

The direction is left to right and downward with no significant forward or backward deviation.

**11. GUNSHOT WOUND OF THE POSTERIOR RIGHT UPPER ARM:**

There is a gunshot wound of entrance of the posterior right upper arm located 5-3/4 inches from the top of the right shoulder and along the posterior midline of the right arm. The circular wound is 1/8 inch in diameter and has a 1/16 inch dry brown marginal abrasion extending from 7 o'clock to 2 o'clock. There is no soot or stippling.

After perforating the skin and subcutaneous tissue of the posterior right upper arm, the bullet subsequently perforates the musculature of the posterior right upper arm and the musculature, subcutaneous tissue and skin of the right upper back.

There is a gunshot wound of exit of the right upper back located 15-1/2 inches from the top of the head and 2 inches posterior to the right midaxillary line. The irregularly-shaped wound measures 3/8 x 1/8 inch and has no marginal abrasion, soot or stippling.

Associated with this wound (as mentioned above) is a charred 3/4 inch moist pink skin bridge that separates the entrance gunshot wound #6 (inferior) from the entrance gunshot wound #11 (superior). There is hemorrhage and pulpifaction of the wound track.

The direction is right to left, downward and slightly front to back.

**12. GUNSHOT WOUND OF THE RIGHT ARM:**

There is a gunshot wound of entrance of the dorsal right forearm (superior) located 15-1/2 inches from the top of the right shoulder and 3/4 inch lateral to the posterior midline of the right arm. The ovoid-shaped wound measures 5/16 x 1/4 inch and has a dry, dark brown, circumferential marginal abrasion that measures 1/8 inch at 12 o'clock, 3/16 inch at 3 o'clock, 1/8 inch at 6 o'clock and 1/16 inch at 9 o'clock. There is no soot or stippling.

After perforating the skin and subcutaneous tissue of the posterior right forearm, the bullet subsequently penetrates the musculature of the right upper arm.

A moderately deformed, copper-jacketed, medium caliber bullet is recovered from the anterior musculature of the right upper arm approximately 10 inches from the top of the right shoulder and approximately midline of the right upper arm. The bullet is photographed, sealed within an appropriately labeled envelope and submitted to a representative of the Chicago Police Department.

Associated with this wound is hemorrhage and pulpification of the wound track.

The direction is back to front and upward with no significant lateral deviation.

### **13. GUNSHOT WOUND OF THE RIGHT FOREARM:**

There is a gunshot wound of entrance of the dorsal right forearm (inferior) located 19-1/2 inches from the top of the right shoulder and along the posterior midline of the right arm. The ovoid-shaped wound measures 1/2 x 1/8 inch and has an irregular, dry, circumferential marginal abrasion that measures 1/8 inch at 12 o'clock, 1/16 inch at 3 o'clock, 1 inch at 6 o'clock, and 1/8 inch at 9 o'clock. There is no soot or stippling.

After perforating the skin and subcutaneous tissue of the dorsum of the right forearm, the bullet penetrates the musculature of the right forearm.

A markedly deformed, large fragment of copper-jacketed bullet is recovered from the right forearm at approximately 17 inches from the top of the right shoulder and approximately posterior midline of the right arm. The projectile is photographed, sealed within an appropriately labeled envelope and submitted to a representative of the Chicago Police Department.

Associated with this wound are fractures of the right radius and ulna. There is hemorrhage and pulpification of the wound track.

The direction is upward and slightly back to front with no significant lateral deviation.

### **14. GUNSHOT WOUND OF THE RIGHT HAND:**

There is a gunshot wound of entrance of the dorsum of the right hand located 24 inches from the top of the right shoulder and



1/2 inch posterior to the lateral midline of the right arm. The slit-like wound measures 3/16 inch and has a moist red marginal abrasion from 3 o'clock to 11 o'clock that measures 5/16 of an inch at 3 o'clock, 1/4 inch at 6 o'clock, and 5/16 of an inch at 9 o'clock. There is a thin, circumferential rim of charred skin. Numerous irregular, dry, dark brown abrasions and apparent pseudo-stippling extend along the 5 o'clock to 11 o'clock margin up to 1 inch at 5 o'clock, 1-3/4 inch at 6 o'clock, 1-1/2 inch at 9 o'clock, and 1/2 at 11 o'clock. No definitive gunpowder residue is identified.

After perforating the skin and subcutaneous tissue of the dorsum of the right hand, the bullet penetrates the musculature of the right hand.

Two fragments of markedly deformed, copper-jacketed projectile are recovered from the dorsum of the right hand at a point approximately 23-1/2 inches from the top of the right shoulder and 1/4 inch posterior to the lateral midline of the right arm. The projectile fragments are photographed, sealed within an appropriately labeled envelope and submitted to a representative of the Chicago Police Department.

Associated with this wound is hemorrhage and pulpifaction of the wound track.

The direction is slightly left to right and slightly upward with no significant forward or backward deviation.

#### **15. GUNSHOT WOUND OF THE RIGHT LOWER BACK:**

There is a gunshot wound of entrance of the right lower back located 28 inches from the top of the head and 1-7/8 inches right of posterior midline. The 3/16 x 1/8 inch ovoid wound has a circumferential, moist, pink marginal abrasion that measures 1/16 inch at 12 o'clock, 1/8 inch at 3 o'clock, 1/16 inch at 6 o'clock and 1/16 inch at 9 o'clock. There is no soot or stippling.

After perforating the skin and subcutaneous tissue of the right lower back, the bullet subsequently perforates the sacrum, the abdominal cavity and the musculature of the left side of the abdomen.

A moderately deformed, copper-jacketed, medium caliber bullet is recovered from the soft tissue of the left abdominal wall approximately 25 inches from the top of the head and approximately 2 inches left of anterior midline. The bullet is photographed, sealed within an appropriately labeled envelope and submitted to a representative of the Chicago Police Department.

Associated with this wound is a fracture of the sacrum as well as hemorrhage and pulpification of the wound track.

The direction is back to front, right to left and upward.

**16. GUNSHOT WOUND OF THE RIGHT UPPER LEG:**

There is a gunshot wound of entrance of the medial right upper leg located 42-1/2 inches from the top of the head and 1/2 inch posterior to the medial midline of the right leg. The ovoid wound measures 1/4 x 3/16 inch and has a dry red-brown marginal abrasion that extends from 7 o'clock to 3 o'clock. The abrasion measures 1/16 inch from 7 o'clock to 9 o'clock and less than 1/16 inch from 9 o'clock to 3 o'clock. There is no soot or stippling.

After perforating the skin and subcutaneous tissue of the medial right upper leg, the bullet subsequently perforates the musculature of the right upper leg and the subcutaneous tissue and skin of the posterior right upper leg.

There is a gunshot wound of exit of the posterior right upper leg located 41-3/8 inches from the top of the head and along the posterior midline of the right leg. The irregularly-shaped wound measures 3/8 x 1/4 inch and has a 3/8 x 1/4 inch brown abrasion that extends along the 12 o'clock to 2 o'clock margin. There is no soot or stippling.

Associated with this wound is hemorrhage and pulpification of the wound track.

The direction is left to right and front to back with no significant vertical deviation.

**II. OTHER INJURIES:**

There are clusters of dry red-brown abrasions on the right shoulder, right side of the chest and dorsum of the right wrist and hand. Scattered larger red-brown abrasions are on the abdomen.

**III. OTHER ITEMS RECOVERED:**

Tiny, white metal fragments of apparent projectile are recovered from between the maxillary teeth, the right upper arm and the decedent's clothing. These fragments are photographed, sealed within appropriately labeled envelopes and submitted to a representative of the Chicago Police Department.

These injuries, having been once described, will not be repeated.

**EVIDENCE SUBMITTED**

The following items are collected, sealed within appropriately labeled containers and submitted to a representative of the Chicago Police Department:

- Clothing
- Blood standard
- Projectiles

**INTERNAL EXAMINATION**

**Body Cavities:** See **Evidence of Injury.** The thoracic and abdominal organs are in their normal anatomic positions. There are no adhesions.

**Head:** See **Evidence of Injury.** The skull is unremarkable. The dura and dural sinuses are unremarkable. The leptomeninges are thin and delicate. The cerebral hemispheres are symmetrical with an unremarkable gyral pattern. The cranial nerves and blood vessels are unremarkable. Sections through the cerebral hemispheres, brainstem and cerebellum are unremarkable. There are no hemorrhages of the deep white matter or the basal ganglia. The cerebral ventricles contain no blood. The brain weighs 1325 grams. The spinal cord as viewed from the cranial cavity is unremarkable.



**Neck:** See **Evidence of Injury.** The hyoid bone is intact.

**Cardiovascular System:** The intimal surface of the abdominal aorta is free of significant atherosclerosis. The aorta and its major branches and the great veins are normally distributed. The pulmonary arteries contain no thromboemboli. The pericardium, epicardium and endocardium are smooth, glistening and unremarkable. The foramen ovale is closed. The coronary arterial system is normally formed and free of significant atherosclerosis. The atrial and ventricular septa are intact. The cardiac valves are unremarkable. The myocardium is dark red-brown and firm and there are no focal abnormalities. The heart weighs 360 grams.

**Respiratory System:** See **Evidence of Injury.** The oropharynx is unobstructed. The laryngeal mucosa is pink, smooth, and without petechiae. The pleural surfaces are smooth and glistening. The major bronchi are unremarkable. Sectioning of the lungs discloses a dark red, moderately congested parenchyma.

**Hepatobiliary System:** The liver is covered by a smooth glistening capsule. The parenchyma is dark red-brown and moderately congested. The liver weighs 1062 grams. The gallbladder contains approximately 10 mL of dark green-brown bile with no calculi.

**Gastrointestinal System:** The esophageal mucosa is gray, smooth, and unremarkable. The stomach contains approximately 20 mL of blood. There are no tablets or capsules. The gastric mucosa has normal rugal folds and is unremarkable. The small and large intestines are externally unremarkable. The appendix is present.

**Genitourinary System:** The left kidney is absent. The capsule of the right kidney strips with ease to reveal a smooth and slightly lobulated surface. The cortex is of normal thickness with well-demarcated corticomedullary junctions. The calyx, pelvis and ureter is unremarkable. The urinary bladder contains approximately 200 mL of clear yellow urine. The mucosa is gray, smooth, and unremarkable. The prostate gland is unremarkable externally.

**Endocrine System:** The thyroid and adrenal glands are unremarkable externally and upon sectioning.

**Lymphoreticular System:** The spleen is covered by a smooth, blue-gray intact capsule. The parenchyma is dark red and firm. The cervical, hilar, and peritoneal lymph nodes are unremarkable.

**Musculoskeletal System:** See **Evidence of Injury**. The clavicles, sternum and pelvis have no fractures.

### **FINDINGS**

I. Gunshot wound of the left scalp (graze wound):

- A. Location: Left parietal scalp.
- B. Injuries: Mild subscalpular hemorrhage and thin subarachnoid hemorrhage.
- C. Direction: Indeterminate.
- D. Range of fire: Indeterminate (no soot or stippling on skin).

II. Gunshot wound of the neck:

- A. Entrance: Left base of the neck.
- B. Path: Perforations of neck musculature and trachea.
- C. Recovery: Medium caliber bullet recovered from the right supraspinatus muscle.
- D. Direction: Left to right, slightly front to back and slightly downward.
- E. Range of fire: Indeterminate (no soot or stippling on skin).

III. Gunshot wound of the left chest:

- A. Entrance: Left upper chest.
- B. Path: Perforations of the musculature of the left chest, left lateral back and left upper arm.
- C. Exit: Posterior left upper arm.
- D. Direction: Front to back, right to left and downward.
- E. Range of fire: Indeterminate (no soot or stippling on skin).

IV. Gunshot wound of the right chest:

- A. Entrance: Right side of the chest.
- B. Path: Perforations of the musculature of the right chest, the right fourth rib and right fourth intercostal muscle, the right lung and the right sixth intercostal muscle.
- C. Recovery: Markedly deformed bullet fragment recovered from the right latissimus dorsi muscle.
- D. Direction: Front to back, left to right and slightly downward.
- E. Range of fire: Indeterminate (no soot or stippling on the skin).

V. Gunshot wound of the left elbow:

- A. Entrance: Lateral left elbow.
- B. Path: Perforations of the musculature of the left upper arm and the left humerus.
- C. Exit: Medial left upper arm.
- D. Direction: Left to right, back to front and slightly upward.
- E. Range of fire: Indeterminate (no soot or stippling on the skin).

VI. Gunshot wound of the right upper arm:

- A. Entrance: Posterior right upper arm.
- B. Path: Perforations of the musculature of the right upper arm and the right humerus.
- C. Exit: Medial right upper arm.
- D. Direction: Back to front, downward and slightly left to right.
- E. Range of fire: Indeterminate (no soot or stippling on the skin).



VII. Gunshot wound of the left forearm:

- A. Entrance: Dorsal left forearm.
- B. Path: Perforations of the musculature of the left forearm, the left radius and the left ulna.
- C. Exit: Medial left forearm.
- D. Direction: Back to front, slightly right to left and slightly downward.
- E. Range of fire: Indeterminate (no soot or stippling on the skin).

VIII. Gunshot wound of the lateral right upper leg:

- A. Entrance: Lateral right upper leg.
- B. Path: Perforations of the musculature of the right upper leg, the pelvic floor and the medial left upper leg.
- C. Recovery: Medium caliber bullet recovered from the medial left upper leg.
- D. Directions: Right to left, downward and slightly front to back.
- E. Range of fire: Indeterminate (no soot or stippling on the skin).

IX. Gunshot wound of the left upper back:

- A. Entrance: Left upper back.
- B. Path: Perforations of the musculature of the left back.
- C. Exit: Left lateral back.
- D. Direction: Right to left and downward with no significant deviation forwards or backwards.
- E. Range of fire: Indeterminate (no soot or stippling on the skin).

X. Gunshot wound of the left elbow:

- A. Entrance: Lateral left elbow.
- B. Path: Perforations of the musculature of the left elbow, the left humerus and the left ulna.
- C. Exit: Medial left elbow.
- D. Direction: Left to right and downward with no significant forward or backward deviation.
- E. Range of fire: Indeterminate (no soot or stippling on the skin).

XI. Gunshot wound of the right upper arm:

- A. Entrance: Posterior right upper arm.
- B. Path: Perforations of the musculature of the right upper arm and right upper back.
- C. Exit: Right upper back.
- D. Direction: Right to left, downward and slightly front to back.
- E. Range of fire: Indeterminate (no soot or stippling on the skin).

XII. Gunshot wound of the right arm:

- A. Entrance: Dorsal right forearm.
- B. Path: Perforation of the musculature of the right upper arm.
- C. Recovery: Medium caliber bullet recovered from the musculature of the anterior right upper arm.
- D. Direction: Back to front and upward with no significant lateral deviation.
- E. Range of fire: Indeterminate (no soot or stippling on the skin).

XIII. Gunshot wound of the right forearm:

- A. Entrance: Dorsal right forearm.
- B. Path: Perforations of the musculature of the right forearm.
- C. Recovery: Large fragment of projectile recovered from the right forearm.
- D. Direction: Upward and slightly back to front with no significant lateral deviation.
- E. Range of fire: Indeterminate (no soot or stippling on the skin).


- XIV. Gunshot wound of the right hand:
- A. Entrance: Dorsum of the right hand.
  - B. Path: Perforations of the musculature of the right hand.
  - C. Recovery: Fragments of projectile recovered from the dorsum of the right hand.
  - D. Direction: Slightly left to right and slightly upward with no significant deviation forward or backwards.
  - E. Range of fire: Indeterminate (no soot or stippling on the skin on the hand).
- XV. Gunshot wound of the lower back:
- A. Entrance: Right lower back.
  - B. Path: Perforations of the sacrum and left abdominal wall musculature.
  - C. Recovery: Medium caliber bullet recovered from the soft tissue of the left abdominal wall.
  - D. Direction: Back to front, right to left and upward.
  - E. Range of fire: Indeterminate (no soot or stippling on the skin).
- XVI. Gunshot wound of the right upper leg:
- A. Entrance: Medial right upper leg.
  - B. Path: Perforation of the musculature of the right upper leg.
  - C. Exit: Posterior right upper leg.
  - D. Direction: Left to right and front to back without significant vertical deviation.
  - E. Range of fire: Indeterminate (no soot or stippling on the skin).
- XVII. Abrasions of the right shoulder, chest, abdomen hand and wrist.
- XVIII. Small, probable projectile fragments recovered from the mouth, skin of the right upper arm and the clothing.
- XIX. Post-mortem toxicology negative for benzoylecgonine, ethanol and opiates.
- XX. Police-involved shooting.



OPINION

Based on the case history and autopsy findings, it is my opinion that LAQUAN MCDONALD, a 17-year-old black male, died as the result of multiple gunshot wounds.

MANNER OF DEATH: Homicide



---

Denika Means, DO  
Assistant Medical Examiner

1/15/2015

WTT:jm  
J: -24  
D: 10/23/14@17:26  
T: 10/24/14@11:56

OFFICE OF THE MEDICAL EXAMINER  
COUNTY OF COOK, ILLINOIS  
TOXICOLOGY REPORT

Page 1 of 1

**FINAL**

M.E. Case: ME2014-01071  
Deceased Name: McDonald, Laquan  
Autopsy Date: 10/21/2014  
Report Date: 12/11/2014  
Pathologist: MEANS, DENIKA

Tox Case: 14-3614  
Gender: Male  
Race: Black  
Age: 17

**Confirmed Positives**

<u>Sample #</u>	<u>Analyte</u>	<u>Sample Type</u>	<u>Methodology</u>	<u>Result</u>	<u>Foot note</u>
-----------------	----------------	--------------------	--------------------	---------------	------------------

**Screen**

<u>Sample #</u>	<u>Analyte</u>	<u>Sample Type</u>	<u>Methodology</u>	<u>Result</u>
01-01	BENZOYLECGONINE	Hospital Specimens	ELISA	Negative
01-01	ETHANOL	Hospital Specimens	GC	Negative
01-01	OPIATES	Hospital Specimens	ELISA	Negative

**Comments**



KOIN, PETER

Toxicologist

Date reviewed: 12/11/2014

**Footnotes**

**Test Panels**

Opiate ELISA Screen includes: Morphine, Codeine