



AUTOPSY REPORT

Case No. OC15-030

July 14, 2015

ON THE BODY OF

Sandra Annette Bland

CAUSE OF DEATH: Hanging

MANNER OF DEATH: Suicide

DATE OF DEATH: July 13, 2015

*SND* MD

Sara N. Doyle, M.D.  
Assistant Medical Examiner

7/22/15

MMDDYY

Sandra Annette Bland

OC15-030

-2-

POSTMORTEM EXAMINATION ON THE BODY OF

Sandra Annette Bland

**HISTORY:** This 28-year-old black woman, positively identified by fingerprint comparison as Sandra Annette Bland, was pronounced dead at 9:06 a.m. on July 13, 2015 in the Waller County Jail at cell block 95, where she was found hanged in her solitary jail cell.

**AUTOPSY:** The autopsy is performed at the Harris County Institute of Forensic Sciences by Assistant Medical Examiner Sara N. Doyle, M.D., at the request and upon the written authorization of the Honorable Charles J. Karisch, Justice of the Peace, Precinct 1, Waller County, Texas, beginning at approximately 10:15 a.m. on July 14, 2015. Texas Ranger Ellison and investigator Parinello of the Waller County Sheriff's office are in attendance.

**CLOTHING AND PERSONAL EFFECTS:** When first viewed, the decedent is clad in two orange shirts, a pair of orange pants, and underlying orange shorts. There are no personal effects.

Received in the body bag with the decedent is a paper bag labeled "Trash Bag Used as Ligature; Removed on 7-13-15 @12:14 PM; Bland, Sandra Annette; B/F 02/07/87; Custodial Death; Waller Co. Jail" containing a transparent white plastic trash bag tied into a ligature, which is subsequently described under the EVIDENCE OF INJURY paragraph.

**EXTERNAL APPEARANCE:** The body is that of a normally developed, 70 inch, 164-1/2 pound black woman who appearance is consistent with the given age of 28 years. The curly black hair measures up to approximately 4-1/2 inches in length. The eyes have brown irides. The conjunctivae have no hemorrhage, petechiae or jaundice. Each earlobe is pierced twice. Multiple tattoos are over the body as documented on photographs. A 1-inch curvilinear scar is at the umbilicus. A 4-inch horizontal linear scar is on the lower abdomen. A 1/4-inch scar is on the lateral left antecubital fossa. A 3/8-inch oval raised scar is on the dorsal left wrist. The oral cavity has natural teeth in good repair. The oral mucosa is atraumatic and has no petechiae. The neck is remarkable for a ligature furrow as subsequently described under the EVIDENCE OF INJURY paragraph. The torso and extremities are normally developed. The fingernails are short and intact. The hands have no injuries. The genitalia, including the labia

SW

Sandra Annette Bland

OC15-030

-3-

majora, labia minora, posterior fourchette, and vaginal canal are free of injuries. Pasty white discharge is at the vaginal introitus. The anus is unremarkable and has no injuries.

POSTMORTEM CHANGES: There is marked rigor mortis of the upper and lower extremities, neck, and jaw. Lividity is blanching, pink-purple and is visible posteriorly in the dependent areas as well as over the palms. The body is cold, subsequent to refrigeration.

THERAPEUTIC INTERVENTION: Defibrillation pads are over the torso. An electrocardiogram adhesive pad is on the upper right arm.

EVIDENCE OF INJURY:

I. HANGING: When first viewed, a ligature furrow is around the neck. Anteriorly, it is oblique, and is located at the level of the superior thyroid cartilage to the right of midline, and above the thyroid cartilage to the left of midline. It cants upward posterior to the left ear across the left side of the neck. It is roughly horizontal at the right side of the neck, canting slightly upward posteriorly. The furrow at the anterior, right lateral, and left lateral neck is dried, brown and ranges from approximately 1/4 to 3/8 inch in width. The highest point of the furrow is posteriorly at the central occipital scalp/superior neck region, where it is located slightly below the occipital prominence, and consists of a faint purple furrow approximately 3/8 - 1/2 inch wide which cants downward toward the right side of the neck. The furrow is absent at the posterior left neck for approximately 2 inches in horizontal dimension.

Internal examination of the anterior and posterior neck strap muscles reveals no focal hemorrhages. Slight drying and compression involve the superficial superior neck strap musculature directly underlying the furrow. The hyoid bone, thyroid cartilage, and cricoid cartilage are intact without fractures. The cervical vertebrae are intact without injury.

No petechiae of the face, conjunctivae, oral mucosa, or airway are identified.

A ligature received in the labeled paper bag previously described consists of a plastic transparent white trash bag which is tied into a slip knot that forms a circle at one end and a knotted area at the opposite end, with two cut ends extending from the knot

SW

opposite the circular area. The circular area formed by the slipknot is approximately 6-1/2 inches in internal diameter. The area from the slip knot of the circular end to the opposite knotted end of the ligature is 21 inches in length. The two cut ends extending from the knotted end opposite the circular area are approximately 5 inches and 3 inches in length. The plastic trash bag ligature and paper bag are photographed, and the ligature is submitted to EVIDENCE in the paper bag in which it was received, placed into an additional outer evidence bag.

II. SUPERFICIAL HEALING CUT MARKS, VOLAR LEFT FOREARM: The volar left forearm contains approximately 25 to 30 horizontal faint linear healing scabbed superficial incised wounds with focal pale, scarred regions of healing, which are parallel and range in length from 3/16 to 1 inch.

III. HEALING BLUNT INJURIES: The superior right shoulder has a 1 inch oval faint purple contusion with underlying red-brown subcutaneous hemorrhage. A 6 by 6 inch area of the right upper back contains multiple scabbed horizontal linear and irregular abrasions ranging from 1/4 to 1-1/2 inch. A 3-inch area of faint red-brown patchy subcutaneous hemorrhage underlies this area of abrasions. A fragment of foreign material consistent with plant (dried leaf) material is adherent to one of the healing abrasions of the upper back, and measures approximately 1/4 inch in greatest dimension. It is photographed and submitted to evidence in an envelope labeled "Foreign material from scabbed area of right upper back".

The right upper extremity has a 1-1/2 inch faint brown-purple contusion of the medial elbow region with underlying red-brown subcutaneous hemorrhage. Multiple adjacent small scabbed healing abrasions ranging from 1/16 to 1/4 inch are also in the medial right elbow region. A 1 inch faint purple-brown contusion is on the dorsal left forearm with underlying red-brown subcutaneous hemorrhage.

The radial left wrist has a 3/8 inch horizontal linear scabbed healing abrasion. The subcutaneous tissue of the left wrist has 3/4 inch areas of brown-red hemorrhage at the radial and ulnar surfaces of the wrist. The right wrist has a 3/4 inch horizontal linear scabbed healing abrasion at the radial edge. The right wrist has faintly visible red-brown subcutaneous hemorrhage approximately 1/4 to 1/2 inch in greatest dimension at the ulnar and radial edges of the wrist.

Sandra Annette Bland

OC15-030

-5-

*The injuries above, having been described, will not be repeated.*

INTERNAL EXAMINATION:

**BODY CAVITIES:** The organs are in their normal situs. The pleural, pericardial, and peritoneal cavities contain no abnormal fluid accumulations or adhesions.

**HEAD:** The scalp has no contusions. The skull has no fractures. There are no epidural, subdural, or subarachnoid hemorrhages. The brain weighs 1325 grams and is normal size and shape. The leptomeninges have no exudates. The cerebral vessels have no aneurysms or atherosclerosis. The external aspects of the brainstem and cerebellum are unremarkable. Coronal sections of the cerebrum reveal no focal lesions of the cortex, white matter, or deep nuclear structures. The ventricles are normal size and configuration. The brainstem and cerebellum have the usual patterns on cut surface.

**NECK:** Evidence of hanging is previously described under EVIDENCE OF INJURY. The cervical vertebrae, hyoid bone, tracheal and laryngeal cartilages, and paratracheal soft tissues have no visible injuries. The upper airway is patent. The tongue is unremarkable.

**CARDIOVASCULAR SYSTEM:** The heart weighs 300 grams and has a right-dominant coronary artery circulation without atherosclerosis of the epicardial vessels. The myocardium has no focal lesions. The left ventricular free wall and interventricular septum are each 1.2 centimeters and the right ventricle is 0.3 centimeters thick. The endocardial surfaces and four cardiac valves are unremarkable. The aorta has no atherosclerosis. The venae cavae and pulmonary arteries contain no thrombi or emboli.

**RESPIRATORY SYSTEM:** The right lung weighs 400 grams and left weighs 350 grams. The lungs are slightly congested and have no masses or consolidation. The bronchi are unremarkable.

**LIVER, GALLBLADDER AND PANCREAS:** The liver weighs 1320 grams and has an intact capsule and brown-red parenchyma without focal lesions. The gallbladder contains 15 milliliters of green bile without stones. The gallbladder mucosa is unremarkable. The pancreas is unremarkable in lobulation, color, and texture.

SM

Sandra Annette Bland

OC15-030

-6-

**SPLEEN AND LYMPH NODES:** The spleen weighs 100 grams and has an intact capsule. The color, red and white, pulp and consistency are unremarkable. There are no enlarged lymph nodes. The bone marrow, where viewed, is unremarkable.

**ENDOCRINE SYSTEM:** The thyroid and adrenal glands are normal color, size, and consistency.

**GENITOURINARY SYSTEM:** The right kidney weighs 125 grams and the left weighs 150 grams. Each kidney has a smooth, red-brown surface with an unremarkable architecture and vasculature. The ureters maintain uniform caliber into an unremarkable bladder which contains less than 1 milliliter of cloudy yellow urine. The ovaries and fallopian tubes are unremarkable. The vagina has no trauma or lesions, and has focal pasty white film over its mucosa. The uterus has a slightly thick, red-tan endometrium and has no evidence of pregnancy. The cervix is unremarkable.

**GASTROINTESTINAL SYSTEM:** The esophagus and gastroesophageal junction are unremarkable. The stomach contains approximately 170 milliliters of gray-tan fluid without solid particles. The gastric mucosa has no focal lesions. The serosal surfaces of the small intestine and large intestine are smooth and glistening. The vermiform appendix is absent, with surgical staples at its resection site.

**MUSCULOSKELETAL SYSTEM:** The vertebrae, clavicles, sternum, ribs, and pelvis have no fractures. Examination of the subcutaneous tissues and musculature of the anterior and posterior torso and upper and lower extremities reveals no hemorrhages or injuries except those as previously described under EVIDENCE OF INJURY.

**TOXICOLOGY:** Specimens including blood, vitreous, urine, bile, stomach contents, liver and brain submitted to toxicology.

**HISTOLOGY:** Specimens including heart, lungs, liver, kidney, spleen, brain, and uterus submitted to histology.

**PHYSICAL EVIDENCE:** Specimens including clothing, ligature (white plastic trash bag) in the paper bag in which it was received with the decedent's body, fingernail scrapings and clippings, sexual assault evidence collection kit, and foreign material from scabbed area of right upper back are sealed in evidence containers and released to Investigator M.

8/10

Sandra Annette Bland

OC15-030

-7-

Parinello of the Waller County Sheriff's Office. (NOTE: Despite absence of injuries to the genitalia or anus, a sexual assault evidence collection kit is obtained should future testing be warranted.)

#### PATHOLOGICAL FINDINGS

- I. Hanging
  - A. Ligature furrow around neck
  - B. Internal examination negative for neck musculature hemorrhages
  - C. Internal examination negative for fractures of hyoid bone, thyroid cartilage, cricoid cartilage and cervical vertebrae
  - D. Investigative information indicates the decedent was found hanging from a beam in her solitary jail cell by a ligature made of a transparent white plastic trash bag
  - E. Ligature (plastic trash bag) recovered and submitted as evidence
- II. Healing superficial parallel horizontal incised wounds numbering approximately 25-30 of volar left forearm
- III. Healing superficial blunt injuries
  - A. Healing abrasions and contusions, right upper back and shoulder
  - B. Healing abrasions and contusions, right elbow region
  - C. Healing contusion, left forearm
  - D. Healing abrasions and contusions, bilateral wrists

MS

Sandra Annette Bland

OC15-030

-8-

HARRIS COUNTY INSTITUTE OF FORENSIC SCIENCES  
1885 OLD SPANISH TRAIL  
HOUSTON, TEXAS 77054-2001

Sara N. Doyle, M.D.  
Assistant Medical Examiner

OC15-030

MICROSCOPIC EXAMINATION

Summary: Five H&E-stained slides are examined.

HEART - Sections from the left and right ventricles have focal mild myocyte hypertrophy and otherwise no significant pathologic change. Three sections of myocardium are examined.

BRAIN - Sections of the hippocampus and frontal lobe have no significant pathologic change.



LUNG - Vasculare congestion. Intra-alveolar edema and congestion. Focal mild peribronchial chronic inflammation.

LIVER - Vascular congestion, otherwise no significant pathologic change.

KIDNEY - Vascular congestion, otherwise no significant pathologic change.

SPLEEN - Congestion of red pulp, otherwise no significant pathologic change.

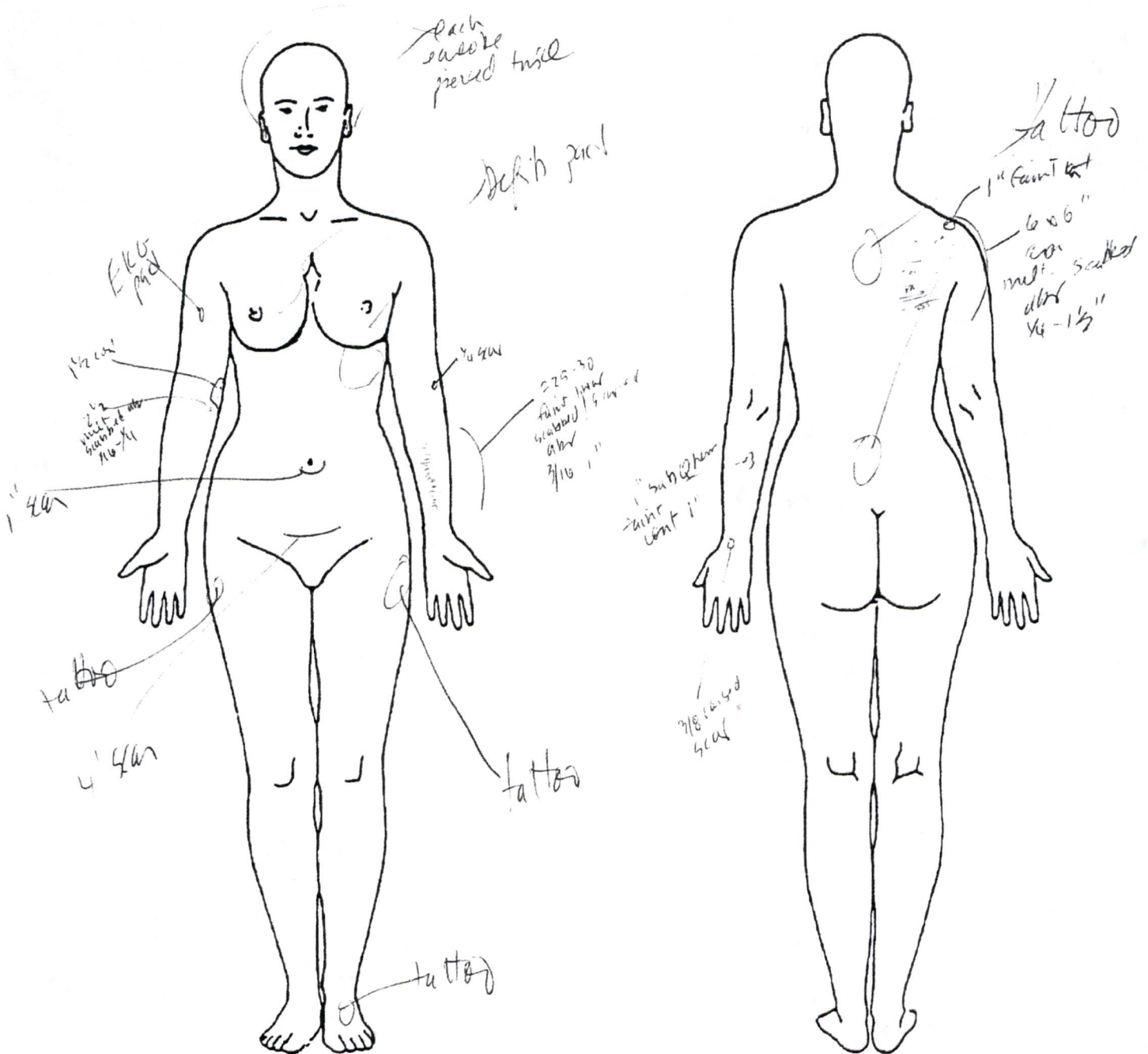
UTERUS - Unremarkable late secretory endometrium and normal myometrium.

 MD   
-----  
Sara N. Doyle, M.D. MMDDYY  
Assistant Medical Examiner





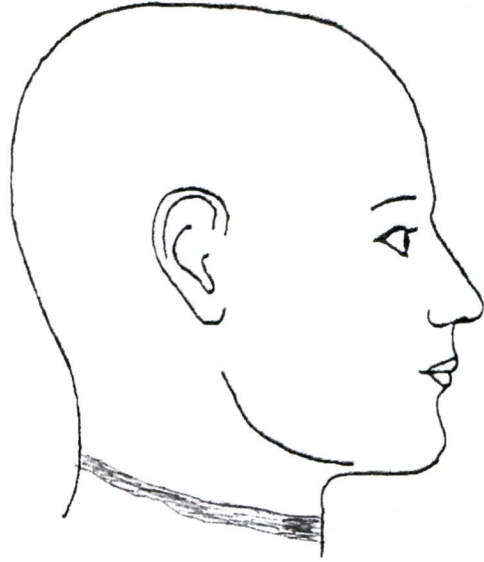
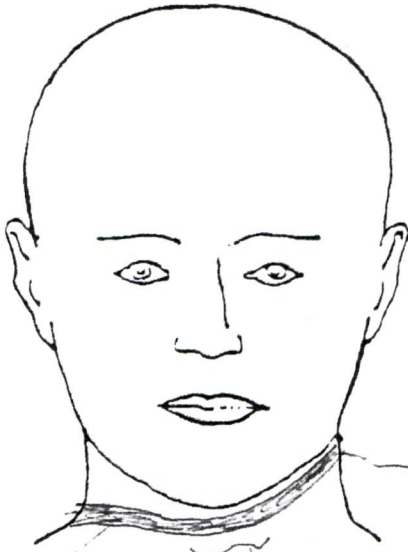
QND Harris County Institute of Forensic Sciences		
Case Number:	<del>MCT</del> OCIS - 030	Page: 1 of 3
Decedent's Name:	Gandra Bland	Length: 70 / Weight: 164.5
Examiner:	Joyl	Date: 7/14/15 Time: 10:15 AM





Harris County Institute of Forensic Sciences

Case Number OCIS-030 Decedent's Name Landia Bland  
 Examiner Doyle Date 7/14/15 Page 2 of 3

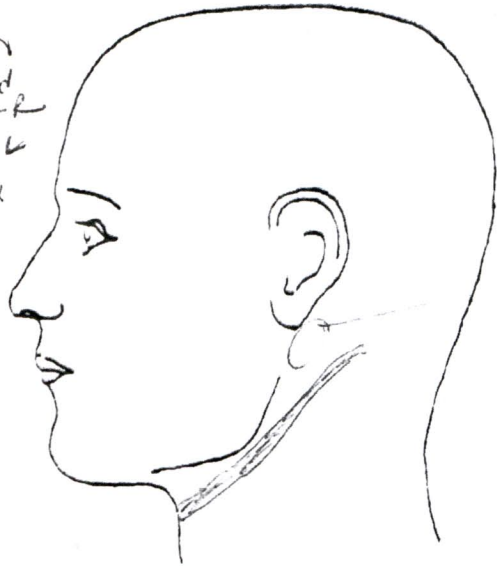
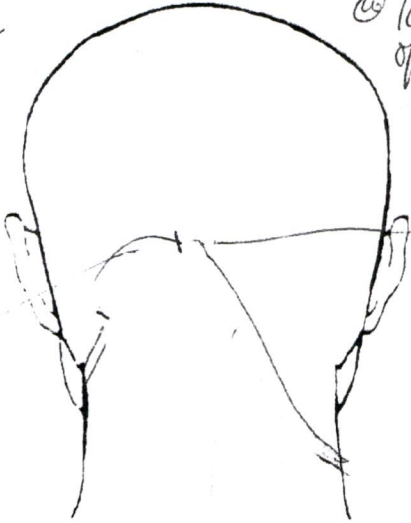
antc  
up to L  
tan

@ level  
of superior  
thyroid  
cart. - R  
above L  
apex

Arrow  
to dry brn  
ant  
1/4 - 3/8" wide

absent  
fines



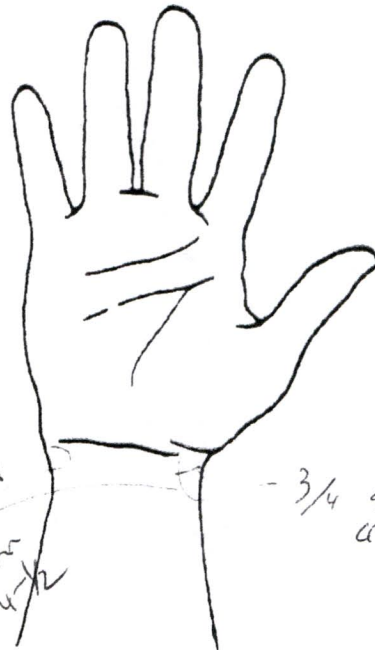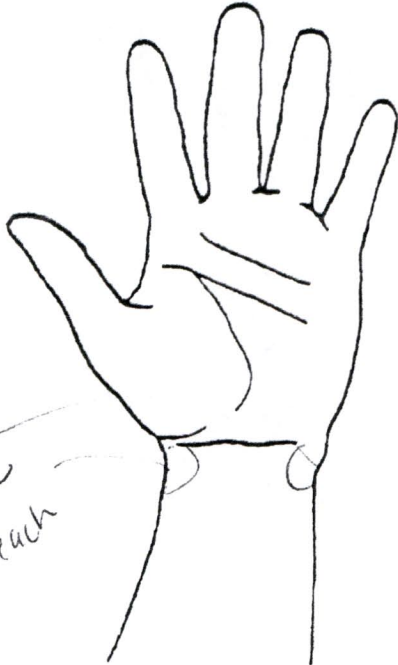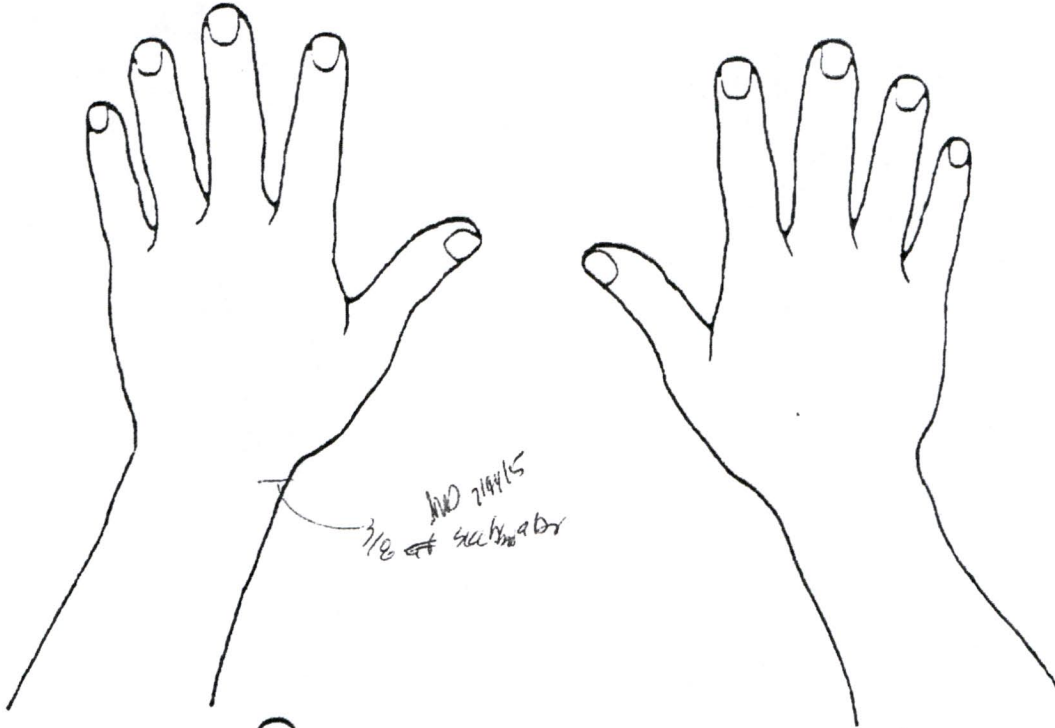
tattoo

1/8 - 1/2  
purple



Harris County Institute of Forensic Sciences

Case Number: <i>DCIS - 030</i>	Decedent's Name: <i>Sandra Bland</i>	
Examiner: <i>Doyle</i>	Date: <i>7/14/15</i>	Page <i>3</i> of <i>3</i>



- 3/4 scabbed  
a by